

# Annals of Clinical and Medical Case Reports

## Case Series Report And Literature Review Of Autoimmune Gastritis: The Vicious Circle Of Failed Helicobacter Pylori Eradication

Yi Ju Xia<sup>1</sup>, Jun Hao Yang<sup>1</sup>, Zu Ping Liu, Sha Gu, WanNi Yu, Zhi Hong Peng<sup>#</sup>, Jian Hua Dai<sup>#</sup>

<sup>1</sup>Department of Gastroenterology, The First Affiliated Hospital of Army Military Medical University, Chongqing 400038, China

### \*Corresponding Author:

Jian Hua Dai and Zhi Hong Peng, Department of Gastroenterology, The First Affiliated Hospital of Army Military Medical University

**Received Date:** 20 May 2025

**Accepted Date:** 25 Jun 2025

**Published Date:** 30 Jun 2025

### Citation:

Jian Hua Dai and Zhi Hong Peng. Case series report and literature review of Autoimmune gastritis. The vicious circle of failed Helicobacter pylori eradication. *Annals of Clinical and Medical Case Reports* 2025; 14: 1-5

### 1. Abstract

**1.1. Objective:** This study aims to evaluate the phenomenon of repeated positive urea breath tests in Autoimmune gastritis (AIG), identify potential causes, and propose appropriate diagnostic and treatment strategies.

**1.2. Methods:** We review of 161 patients with refractory Helicobacter pylori (*H. pylori*) infections admitted to our hospital from March 2023 to December 2023. After *H. pylori* culture, 56 cases tested negative, including 9 cases of AIG. Among the 105 cases testing positive, only 1 was diagnosed with AIG. We retrospectively analyzed cases of AIG with a positive urea breath test and developed a treatment plan.

**1.3. Results:** In patients with AIG, 88.9% showed false positive urea breath tests, while only 5.6% had co-infection with *H. pylori*.

**1.4. Conclusion:** In patients with AIG and false positive urea breath tests, intragastric colonization by urobilinase-producing Gram-positive bacteria should be considered. "Quagmire elimination" should be avoided. *H. pylori* infection must be confirmed through culture or pathology, followed by a standardized eradication plan.

**1.5. Clinical Trial Registration:** China Medical Research Registration and filing information system pid:256932

**2. Keywords:** Autoimmune gastritis; Helicobacter pylori infection; Helicobacter pylori culture

### 3. Background

AIG is an immune-mediated, organ-specific, chronic inflammatory disease characterized by the destruction of gastric lining cells. This leads to a significant decrease in gastric acid secretion and induces hypergastrinemia through negative feedback. AIG is often associated with the presence of anti-mural cell and/or

anti-endogenin antibodies. [1-3] These alterations impair mural cell function, leading to malabsorption of iron, vitamin B12, and other micronutrients, which can result in pernicious anemia.[4] AIG is frequently accompanied by neuroendocrine tumors, gastric cancer, and other complications.[5]

The global detection rate of AIG ranges from 0.5% to 4.5%,[6] with higher rates reported in Northern Europe and North America. In China, the detection rate is approximately 0.9%.[7] The specific etiology of AIG remains inconclusive. Elevated levels of immune-related miRNA have been detected in AIG cases infected with *H. pylori*. It is suggested that the progression of AIG or tumorigenesis may be associated with *H. pylori* infection.[pylor 8]

*H. pylori* can cause gastric mucosal atrophy, typically starting in the gastric antrum and gradually involving the gastric body. In AIG, atrophy of the gastric body predominates due to the destruction and absence of mural cells. The extent of gastric mucosal atrophy makes it difficult for to colonize. Most patients with AIG who test positive on the urea breath test remain positive even after repeated *H. pylori* eradication therapies. T. Furuta et al. suggested that a positive urea breath test in AIG cases may be a false positive. [9] Relying solely on a positive urea breath test for further treatment in AIG patients is erroneous. In this study, we analyzed the clinical data of nine patients with AIG who tested positive on the urea breath test and reviewed the relevant literature to clarify the relationship between AIG and *H. pylori* infection, aiming to establish rational diagnostic and treatment approaches.

### 4. Objects and Methods

Testing for *H. pylori* infection is categorized into non-invasive and invasive tests. Non-invasive tests, such as the Urea Breath Test (UBT), are commonly used for initial screening and to evaluate treatment efficacy. Invasive tests include the rapid urease test, *H. pylori* culture, drug sensitivity test (DST), and pathology. *H. pylori* culture, drug sensitivity testing, and pathology are considered the gold standards for diagnosing *H. pylori* infection.

This study employed a retrospective analysis, collecting data from 161 patients with refractory *H. pylori* infections, diagnosed via culture at the Department of Gastroenterology, First Affiliated Hospital of the Army Military Medical University of the People's Liberation Army, between March 2023 and December 2024. Of these, 56 cases tested negative for *H. pylori*, with 8 cases of AIG; 105 cases tested positive, with 1 case of AIG. To investigate the causes of a positive urea breath test in AIG patients, we focused on these 9 AIG cases and analyzed their basic conditions, laboratory test results, gastroscopic findings, and pathological examinations. Inclusion criteria: 1. Patients who underwent at least two consecutive standardized eradication treatments, yet remained positive on the urea breath test and had *H. pylori* culture results; 2. Endoscopic findings in AIG observation showing significant atrophy of the gastric body and mild or no atrophy in the gastric antrum; 3. Positive anti-mural cell antibody and/or anti-endogenin antibody.

Exclusion criteria: 1. Multifocal atrophic gastritis; 2. No *H. pylori*

# Annals of Clinical and Medical Case Reports

culture performed; 3. Inability to follow up regularly due to patient-related reasons.

All patients provided written informed consent to participate in this study and for the publication of relevant test and examination data.

## 5. Results

### 5.1. General and Clinical Presentation

This study included 161 patients with refractory *H. pylori* infections, collected from the Department of Gastroenterology, First Affiliated Hospital of the Army Military Medical University of the People's Liberation Army of China, between March 2023 and December 2023. Among these, 9 cases of AIG were identified. *H. pylori* culture results were negative in 8 cases and positive in 1 case. All 9 patients were included in the study. Basic information on these patients is shown in Table 1. All patients tested positive for anti-mural cell antibodies and/or anti-endogenin antibodies and had received at least two courses of standardized *H. pylori* treatment. Their clinical manifestations were nonspecific gastrointestinal symptoms, including abdominal distension, discomfort, and regurgitation.

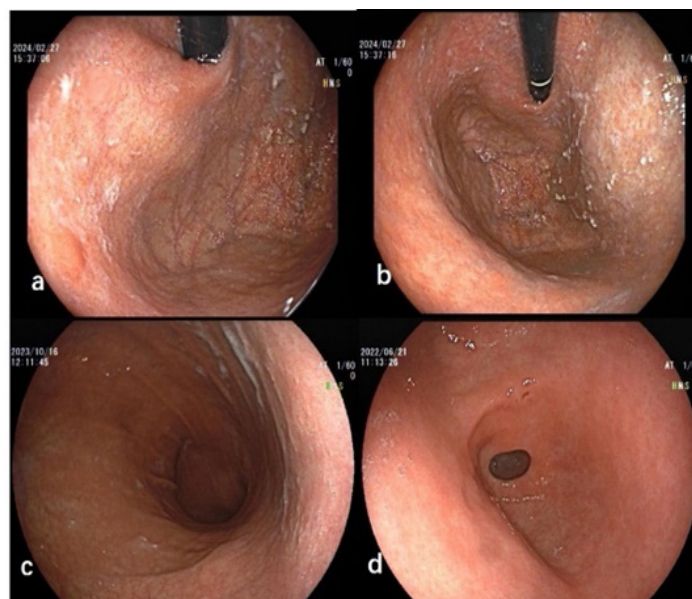
**Table 1. Basic information of patients**

	SEX	Age (years)	urea breath test	Gastroscopic appearance	Anti GPC/IF antibody	<i>H. pylori</i> culture	Number of antimicrobial treatments
1	female	60	(+)	Autoimmune gastritis	(+)	(+)	3
2	female	51	(+)	Autoimmune gastritis	(+)	(+)	2
3	female	49	(+)	Autoimmune gastritis	(+)	(+)	2
4	female	60	(+)	Autoimmune gastritis	(+)	(+)	3
5	female	46	(+)	Autoimmune gastritis	(+)	(+)	3
6	female	52	(+)	Autoimmune gastritis	(+)	(+)	2
7	female	54	(+)	Autoimmune gastritis	(+)	(+)	3
8	male	57	(+)	Autoimmune gastritis	(+)	(+)	2
9	female	65	(+)	Autoimmune gastritis	(+)	(+)	2

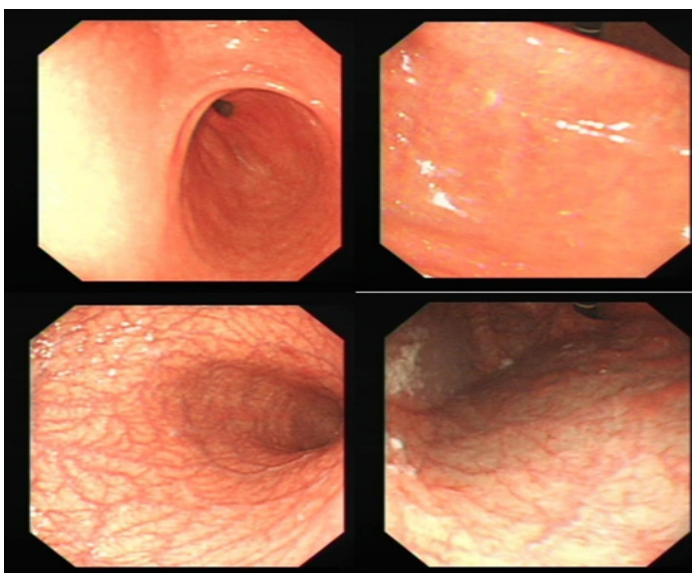
### 5.2. Endoscopic Findings In AIG Manifestations

Endoscopic findings in AIG typically show atrophy of the gastric body mucosa, predominantly with inverse atrophy.[1,10] All 9 cases in this study exhibited this feature, with uniformly thin gastric body mucosa and submucosal vascular permeability under full insufflation. Highly atrophic manifestations of the O-P typology were observed in all cases. The gastric fundus and body exhibited increased mucus adherence (Figures 1 and 2).

In cases with pseudo-positive *H. pylori* culture in AIG, the gastric antrum showed mild atrophic changes, which could not be easily removed by water rinsing. The gastric fundus and body had thick mucus that adhered strongly (Figure 1). In the *H. pylori* culture-positive atrophic gastritis cases, the gastric fundus and body exhibited white mucus and scattered pseudo-polyp formations in the gastric body. The atrophy in the gastric antrum was more severe, and the degree of gastric atrophy approached that of the gastric body. The gastric mucosal mucus in these cases was thin, light, and could be easily removed by water rinsing (Figure 2). After standard *H. pylori* eradication treatment, repeat gastroscopy showed that the atrophy of the gastric antrum and angle had reversed compared to the pre-eradication status (Figure 3).



**Figure 1: Dense, sticky mucus and scattered minute whitish protrusions. (a,b) Typical sticky adherent mucus. The gastric mucosa is thin, with visible submucosal blood vessels (a,b,c).**



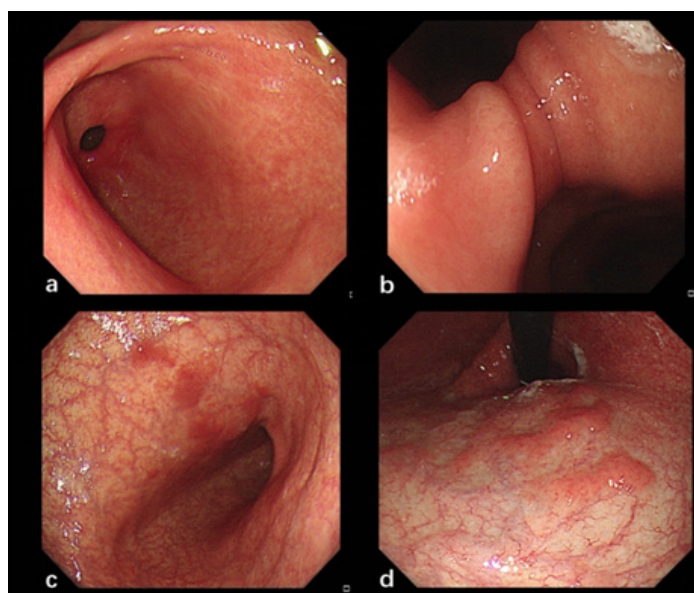
**Figure 2: Hp culture-positive patient showing significant atrophy of the gastric antrum, angle, and body before Hp eradication.**

### 5.3. Pathological Examination

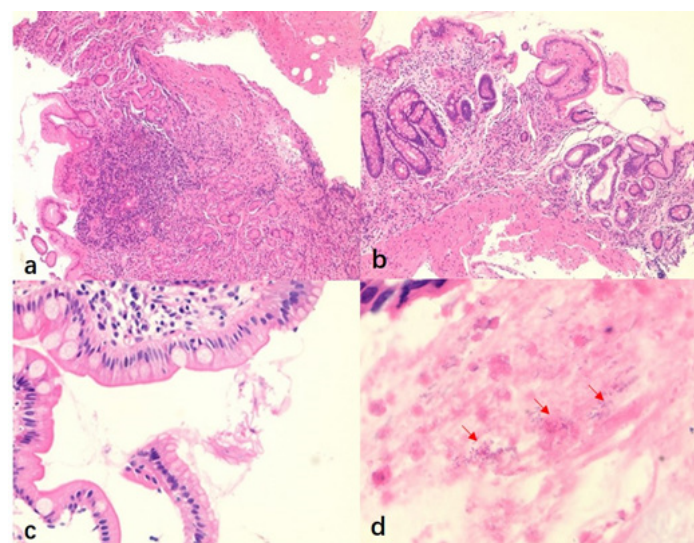
Biopsies of the gastric body and antrum were performed in all 9 patients. Pathological examination revealed a microscopic pattern of inverse atrophy and mucosal allodynia, which are characteristic of AIG. Laboratory tests showed positive anti-mural cell antibodies and/or anti-endogenin antibodies, confirming the diagnosis of AIG. Atrophy primarily affected the gastric body, which was more severely damaged than the gastric antrum. The gastric fundus exhibited moderate to severe atrophy, with a ratio of the lesser concave epithelium to the fundus gland of about 1-2:1. In three cases, the structure of the fundus gland was unclear, with individual mural cells and more principal cells. In one case, the

# Annals of Clinical and Medical Case Reports

fundus gland was almost completely atrophied (Figure 4b). Some cases showed pseudo-pyloric glandular atrophy (Figure 4a). Small concave epithelium appeared distorted and disorganized, with glands twisted at the neck. In all cases, glands showed marked enteric changes (Figure 4c), with no neuroendocrine cell hyperplasia. The gastric body was infiltrated by numerous scattered lymphocytes in the lamina propria, a few plasma cells, and secondary lymphoid follicle formation. In contrast, inflammation in the antrum was much milder, with scattered lymphocyte and plasma cell infiltration and no lymphoid follicle formation. Mucus adhered to the mucosal surface, and suspicious bacteria were detected in the mucus of the gastric body by oil microscopy (Figure 4d). Using methylene blue staining and oil microscopy, a few bacilli were identified as rod-shaped, sky-blue organisms (Figure 5), confirming Hp infection.

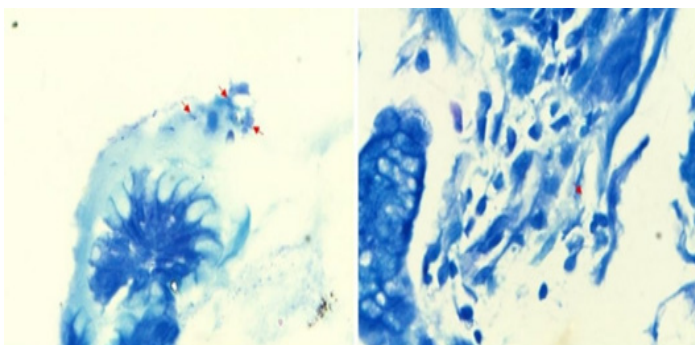


**Figure 3: Hp culture-positive patients, all of whom showed atrophy of the gastric sinus before Hp eradication.**



**Figure 4 HE staining, oil microscopy: Suspicious heterobacterial organisms were detected in the mucus,**

**identified by their granular blue-brown morphology, which differs from the comma- and rod-shaped morphology of Hp.**



**Figure 5 H. pylori (merocyanine) staining (oil microscopy): The background appears blue, with a few bacilli staining as rod-shaped, sky-blue organisms, indicating Hp infection.**

## 6. Treatment

In AIG patients with confirmed H. pylori infection by culture, a regimen of PPI + amoxicillin (0.75 g orally, day 4) was used. The urea breath test became negative after 1 month of discontinuing the medication.

## 7. Discussion

In this study, 56 out of 161 patients with refractory H. pylori infection had negative culture results, 8 of which were diagnosed with AIG. The cause for the remaining 48 negative culture results needs further clarification. The false-negative rate for H. pylori culture is typically 10%, with possible causes including recent use of PPI or antibiotics. Eighteen cases had taken PPI or antibiotics within 2 weeks before culture, potentially affecting the results. Additionally, 14 patients had a urea breath test DOB value of less than 10.0, which was considered a test error, and the overall results were within the normal error range.

Among the 9 patients with AIG and refractory H. pylori infection, 8 had negative culture results. All of these patients had received at least two consecutive standardized eradication treatments, yet the urea breath test remained positive, leading to a clinical misclassification of treatment failure or refractory H. pylori infection. The presence of a false positive urea breath test was confirmed based on H. pylori culture results.

### 7.1. AIG patients with a positive urea breath test are mostly uninfected with H. pylori

It has been suggested that most cases of AIG are associated with H. pylori infection. Pernicious anemia was once considered an exclusive complication of AIG and was shown to be accompanied by H. pylori infection.[11-13] H. pylori infection causes inflammatory changes in the gastric body, damaging mural cells and leading to further development of PCA production and atrophy.[14] In contrast, atrophy in AIG can be partially ameliorated after H. pylori eradication.[15-16] Based on these histologic and clinical similarities, it has been hypothesized that classical AIG may be triggered by H. pylori infection. However, many studies classified H. pylori infection as positive based on a positive urea breath test, fecal antigen, H. pylori antibody titer,

# Annals of Clinical and Medical Case Reports

or culture test. This approach did not exclude false positives and may have overestimated the prevalence of *H. pylori* infection in AIG.

In a study of 404 patients with *H. pylori* infection, it was found that AIG patients were often misdiagnosed with refractory *H. pylori* infection. This was likely due to urease-positive bacteria, other than *H. pylori*, colonizing the gastric juice, which led to false positive urea breath test (13C-UBT) results.[9] Among the 161 patients with refractory *H. pylori* infection in our study, 9 were diagnosed with AIG, 8 of whom had negative *H. pylori* culture results, as previously reported. Endoscopic findings in AIG examination in all cases revealed a high degree of atrophy, with large amounts of sticky mucus adhering to the gastric body. Histologically, AIG is classified into early, intermediate, and late stages based on the degree of atrophy.[10,17-20] However, early and intermediate stages are difficult to detect, and most patients were already in the severe atrophy stage. *H. pylori* is difficult to colonize in severely atrophied mucosa. Therefore, we consider that these patients had either been successfully eradicated or were never infected with *H. pylori*.

## 7.2. Reasons for false-Positive *H. pylori* infection in AIG

We reviewed the literature and concluded that flora imbalance is the primary cause of false positive urea breath tests in AIG patients. For a long time, the stomach was considered a sterile organ, a view that was overturned with the discovery of *H. pylori*. With the advancement of high-throughput sequencing, several dominant bacterial phyla have been identified in the stomach, including Ascomycetes, Firmicutes, Anaplasma, Actinobacteria, and Clostridia.[21-22] *H. pylori* produce urease, which breaks down urea, and the urea breath test is designed to detect urease activity. However, *H. pylori* is not the only urease-producing microorganism in the stomach. A study by Osaki et al. [23] found that microorganisms such as *Aspergillus*, *Citrobacter fumigatus*, *Klebsiella pneumoniae*, *Enterobacter cloacae*, and *Staphylococcus aureus*, which colonize the oral cavity and stomach, also produce urease and can lead to false positive urea breath test results. These microorganisms' urease activity is not easily detected in the acidic environment of a normal stomach. However, in AIG, the gastric body shows a high degree of atrophy, decreased gastric acid secretion, and increased intragastric pH, which disrupts the intragastric flora. Therefore, the intragastric flora in AIG patients significantly differs from that of the normal population. In AIG, Streptococcaceae is the dominant flora, while the proportion of *Campylobacter* and *Haemophilus* increases. [24-25] Both *Campylobacter* and *Haemophilus* have urease activity, leading to false positive urea breath test results. The repeated positive urea breath test in *H. pylori* -uninfected AIG patients has created a clinical dilemma of "removing bacteria from the quagmire." Additionally, gender factors may contribute to false positive urea breath test results in AIG. Studies analyzing intragastric flora in healthy individuals found that females had richer bacterial communities compared to males, but the diversity of their flora was relatively low.[24] In contrast, in AIG patients, no significant gender differences were found in bacterial communities. However, male AIG patients exhibited significantly less intragastric flora diversity than females, who showed the opposite trend.

Specifically, bacteria such as *Clostridium* phylum, *Diplococcus* spp., *Haemophilus* spp, and *Neisseria* spp. were more common in female patients. [26] Some of these bacteria, such as *Neisseria* spp., also have urease activity, which could contribute to false positive urea breath test results.

## 7.3. True *H. pylori* infection in AIG

Our study also identified one case of positive *H. pylori* culture among nine patients with a positive urea breath test in combination with AIG. According to *H. pylori* guidelines, immunohistochemistry of gastric mucosal biopsy is the most reliable and reproducible method for determining *H. pylori* colonization. Pathologic examination of this patient revealed the presence of *H. pylori* in the gastric sinus tissue, but not in the gastric body tissue. Due to persistent inflammation, the gastric sinus exhibited glandular atrophy and intestinal metaplasia. This case showed more atrophy and chronic inflammation in the sinus during gastroscopy compared to *H. pylori* -negative AIG (e.g., Figure 2.d). Previous studies have reported yellow tumors or proliferative changes in *H. pylori* -infected gastric sinuses. [27] A Japanese study defined *H. pylori* association based on IgG antibody levels: values less than 3 were considered *H. pylori* -unrelated, and values greater than 3 were considered *H. pylori* -related. [28] *H. pylori* is difficult to colonize in severely atrophied gastric body tissues, but it was found in gastric sinus tissues. In patients with AIG, a positive repeated urea breath test does not fully confirm true *H. pylori* infection.

We treated the AIG patient with *H. pylori* infection using an eradication regimen of acid-suppressing agents. Over one month later, the urea breath test became negative, and endoscopic examination revealed a reduction in inflammatory and atrophic changes in the gastric sinus. This suggests that *H. pylori* colonization in the stomach is influenced by the thickness of the gastric mucosal epithelium and pH. Furthermore, the modified acid-suppressing eradication regimen (dual therapy: high-dose PPI + 1 antibiotic) proved effective. However, whether other factors contribute to *H. pylori* colonization and the need for standardized treatment of AIG with *H. pylori* infection require further investigation.

We have encountered the phenomenon of "quagmire decontamination" in our clinical practice. For refractory *H. pylori* infection, it is essential to first confirm whether the patient has AIG. AIG is difficult to colonize with *H. pylori* due to gastric mucosal atrophy. Even if the urea breath test is positive, we should be cautious of false positives. It is possible, however, that urease-secreting microorganisms can colonize the area. *H. pylori* culture and histopathological examination can clarify whether there is a true *H. pylori* infection and whether anti-*H. pylori* therapy is necessary. For AIG with *H. pylori* infection, our eradication regimen, which involved a triple therapy after acid-suppressing agents were reduced, showed positive clinical results. More clinical evidence is needed to establish standardized treatment regimens.

## References

1. Neumann, et al. Autoimmune atrophic gastritis—pathogenesis, pathology and management. *Nat. Rev.*

# Annals of Clinical and Medical Case Reports

- Gastroenterol. Hepatol. 2013; 10, 529–541.
2. Minalyan, A. et al. Autoimmune atrophic gastritis: Current perspectives. *Clin. Exp. Gastroenterol.* 2017, 10, 19–27.
3. Annibale, B. et al. A current clinical overview of atrophic gastritis. *Expert. Rev. Gastroenterol. Hepatol.* 2020, 14, 93–102.
4. Hershko C, et al. The anemia of achylia gastrica revisited. *Blood Cells Mol Dis.* 2007;39: 178-183.
5. Agustin Gonzalez, et al. Mucocutaneous Manifestations in Autoimmune Gastritis: A Prospective Case-Control Study. *Am J Gastroenterol.* 2021 December 01; 116(12): 2374–2384.
6. Massironi SA, et al. The Changing Face of Chronic Autoimmune Atrophic Gastritis: An Updated Comprehensive Perspective. *Autoimmun Rev.* 2019, 18:215–222.
7. Yu Chen, et al. A real-world study on the characteristics of autoimmune gastritis: A single-center retrospective cohort in China. *Clin Res Hepatol Gastroenterol.* 2025 Feb 15;49(4):102556.
8. Fabiana Zingone, et al. autoimmune atrophic gastritis: the role of mirnas in relation to helicobacter pylori infection. 2022 Jul 22:13:930989.
9. Furuta T, et al. High incidence of autoimmune gastritis in patients misdiagnosed with two or more failures of H. pylori eradication. *Aliment Pharmacol Ther.* 2018; 48:370–377.
10. Coati, I. et al. Autoimmune gastritis: Pathologist's viewpoint. *World J. Gastroenterol.* 21, 12179–12189 (2015).
11. Toh BH, et al. Pernicious anemia. *N Engl J Med* 1997; 337:1441–1448.
12. Ma JY, et al. Positive correlation between H, K-adenosine triphosphatase autoantibodies and Helicobacter pylori antibodies in patients with pernicious anemia. *Scand J Gastroenterol* 1994;29: 961–965.
13. Annibale B, et al. Two-thirds of atrophic body gastritis patients have evidence of Helicobacter pylori infection. *Helicobacter* 2001; 6:225–233.
14. Negrini R, et al. Helicobacter pylori infection induces antibodies cross-reacting with human gastric mucosa. *Gastroenterology* 1991; 101: 437–445.
15. Stolte M, et al. Cure of autoimmune gastritis by Helicobacter pylori eradication in a 21-year-old male. *Z Gastroenterol* 1998; 36: 641–643
16. Müller H, et al. Healing of active, non-atrophic autoimmune gastritis by H. pylori eradication. *Digestion* 2001; 64: 30–39
17. Stolte M, et al. Active autoimmune gastritis without total atrophy of the glands. *Z Gastroenterol.* 1992; 30:729–735.
18. Solcia E, et al. Distinct patterns of chronic gastritis associated with carcinoid and cancer and their role in tumorigenesis. *Yale J Biol Med.* 1992; 65:793–804.
19. Eidt S, et al. The histopathological spectrum of type A gastritis. *Pathol Res Pract.* 1996; 192:101–6. 58.
20. Neumann WL, et al. Autoimmune atrophic gastritis—pathogenesis, pathology and management. *Nat Rev Gastroenterol Hepatol.* 2013;10: 529–541.
21. Bik EM, et al. Molecular analysis of the bacterial microbiota in the human stomach[J]. *Proc Natl Acad Sci U S A*, 2006, 103:732-737.C
22. Gerardo, et al. The human gastric microbiota: Is it time to rethink the pathogenesis of stomach diseases? [J]. *United European Gastroenterology Journal*, 2015, 3(3):255-260.
23. Osaki T, et al. Urease-positive bacteria in the stomach induce a false-positive reaction in a urea breath test for diagnosis of Helicobacter pylori infection. *J Med Microbiol.*2008;57:814-819.
24. Parsons BN, et al. Comparison of the human gastric microbiota in hypochlorhydric states arising as a result of Helicobacter pylori-induced atrophic gastritis, autoimmune atrophic gastritis and proton pump inhibitor use. *PLoS Pathog.* 2017Nov2;13(11): e1006653.
25. Saxena A, et al. Helicobacter pylori: Perturbation and restoration of gut microbiome. *J Biosci.* 2020;45(1):110.
26. Pivetta G, et al. Gastric Microbiota Gender Differences in Subjects with Healthy Stomachs and Autoimmune Atrophic Gastritis. *Microorganisms.* 2023 Jul 29;11(8):1938.
27. Toh BH, et al. Pernicious anemia. *N Engl J Med* 1997; 337:1441–1448.
28. Takahisa Furuta, et al. Relationship among Autoimmune Gastritis, H.pylori Infection and H. pylori Eradication. *Stomach and Intestine*, 2019;54(7):80-85.