

A Male Patient with Spontaneous Coronary Artery Dissection and a Bicuspid Aortic Valve

Zachary Robert Caverley^{1*} and Lori M. Tam²

¹Cardiology Physician Assistant – Providence Oregon Cardiology Group, 1355 Exchange St, Astoria, OR 97103,

²General Cardiologist – Providence Oregon Cardiology Group, 9205 SW Barnes Road, Portland OR 97225

***Corresponding Author:**

Zachary Robert Caverley,

Cardiology Physician Assistant – Providence Oregon Cardiology Group, 1355 Exchange St, Astoria, OR 97103,

Tel: (616) 894-4365

Author Contributions:

Zachary R. Caverley: Conceptualization, Writing (Original Draft), Visualization
Lori M. Tam: Resources, Writing (Review & Editing), Supervision

Received Date: 04 March 2024

Accepted Date: 21 March 2024

Published Date: 27 March 2024

Citation:

Zachary Robert Caverley. A Male Patient with Spontaneous Coronary Artery Dissection and A Bicuspid Aortic Valve. *Annals of Clinical and Medical Case Reports* 2024; 4

1. Abstract

Spontaneous coronary artery dissection (SCAD) is a rare cause of myocardial infarction (MI) predominantly seen in females. SCAD in males can occur, but at a much lower reported incidence rate. The disease is associated with connective tissue disorders as well. There have been no documented clear associations studied between the presence of bicuspid valve aortopathy and occurrence of SCAD. We present a case of a male suffering from SCAD with recurrent presentations due to lesion extension who incidentally was discovered to have a bicuspid aortic valve with ascending aorta dilatation. This case displays the ongoing importance of screening SCAD patients for additional vascular diagnoses while also showing the unfortunately common recurrence of chest discomfort symptoms in this population.

2. Introduction

Spontaneous coronary artery dissection (SCAD) is a rare and emergent condition where a tear in the intima media or an intramural hematoma of

the coronary artery produces ischemia to the myocardium – mimicking coronary atherosclerotic obstruction. SCAD is typically found in younger and middle-aged females (around 87-95% of cases) [1] and has a relatively high rate of recurrence with one prospective cohort demonstrating a 10.4% recurrence rate [2]. This same cohort indicates a high association between SCAD and connective tissue disorders. It is estimated that connective tissue disorders and arteriopathies (Marfan’s disease, Loeys-Dietz, Ehlers-Danlos) are associated with increased risk for SCAD although these only account for 5-9% of cases [1]. Bicuspid aortic valve is the most common congenital heart defect in the US, occurring in up to 0.5%-2% of the population. The aortopathy associated with bicuspid aortic valve can result in aortic aneurysm formation and increased risk for aortic dissection and rupture [3]. We present a case in a younger male patient with a bicuspid aortic valve and an associated aortopathy who presents with myocardial infarction from spontaneous coronary artery dissection.

3. Presentation and History

A 45-year-old Caucasian male presented to the Emergency Department (ED) by emergency medical transport (EMS) with chest pain feeling like a “muscle spasm.” He rated the pain as 6/10 which improved to 1/10 upon arrival to the ED. There were no known exacerbating factors, and his associated symptoms included dyspnea, lightheadedness, and diaphoresis. Patient had no significant known cardiac history and informed the ED team he had recently “ran a half marathon.” Family history was obtained and was positive for paternal grandfather having “four heart attacks” and having a father who received balloon angioplasty to a coronary artery. Patient denied history of tobacco, alcohol, or illicit drug abuse. Physical exam by the ED Physician was unremarkable.

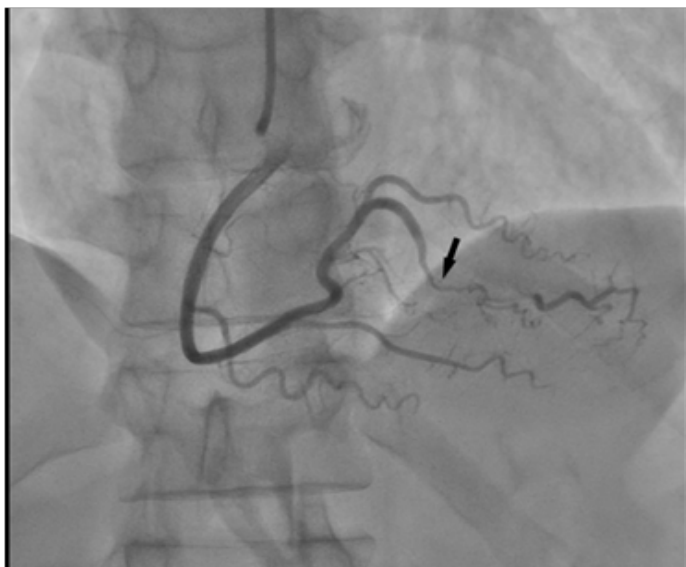
4. Workup

ECG from EMS revealed sinus bradycardia with ST elevation in leads II, III, a VF, V5, V6. No prior study was available for comparison. Repeat ECG demonstrated sinus bradycardia at a rate of 53 bpm and T-wave flattening/inversions in leads III and a VF with resolution of ST elevations. Troponin was <0.01 (normal range less than 0.05) and otherwise labs were unremarkable with no significant kidney dysfunction or anemia. Given concerning pre-hospital ECG, interventional cardiologist was consulted given likely diagnosis of ACS, and the patient was transferred to cath lab. Patient underwent urgent coronary angiogram revealing severe and diffuse mid-segment stenosis of a large right posterolateral branch (RPL1) consistent with a type II a SCAD lesion (Figure 1).

Figure 1: 1st Coronary Angiogram Findings. Coronary Angiogram demonstrating type IIa SCAD lesion of the right posterolateral branch with

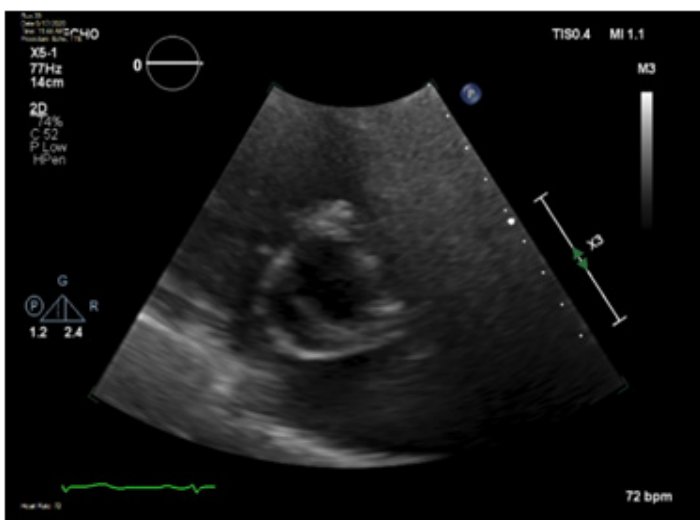
Annals of Clinical and Medical Case Reports

classic tapering appearance followed by distal reopening of the vessel.



Given resolution of angina symptoms, medical management was recommended and no PCI was performed – consistent with current consensus recommendations which recommend conservative management in clinically stable patients without ongoing ischemic symptoms or high risk findings. Subsequent 2D Transthoracic Echocardiogram (TTE) revealed normal left ventricular ejection fraction (LVEF) of 65% with bicuspid aortic valve and 4.0 cm dilatation of the ascending aorta (Figure 2).

Figure 2: Echocardiographic Findings. Short axis view during a 2D Echocardiogram demonstrating a bicuspid aortic valve.



Computed Tomography Angiography (CTA) of neck, chest, and abdomen did not demonstrate Fibromuscular Dysplasia (FMD), and confirmed presence of ascending aortic dilatation measuring 4.1 x 4.1 cm (Figure 3).

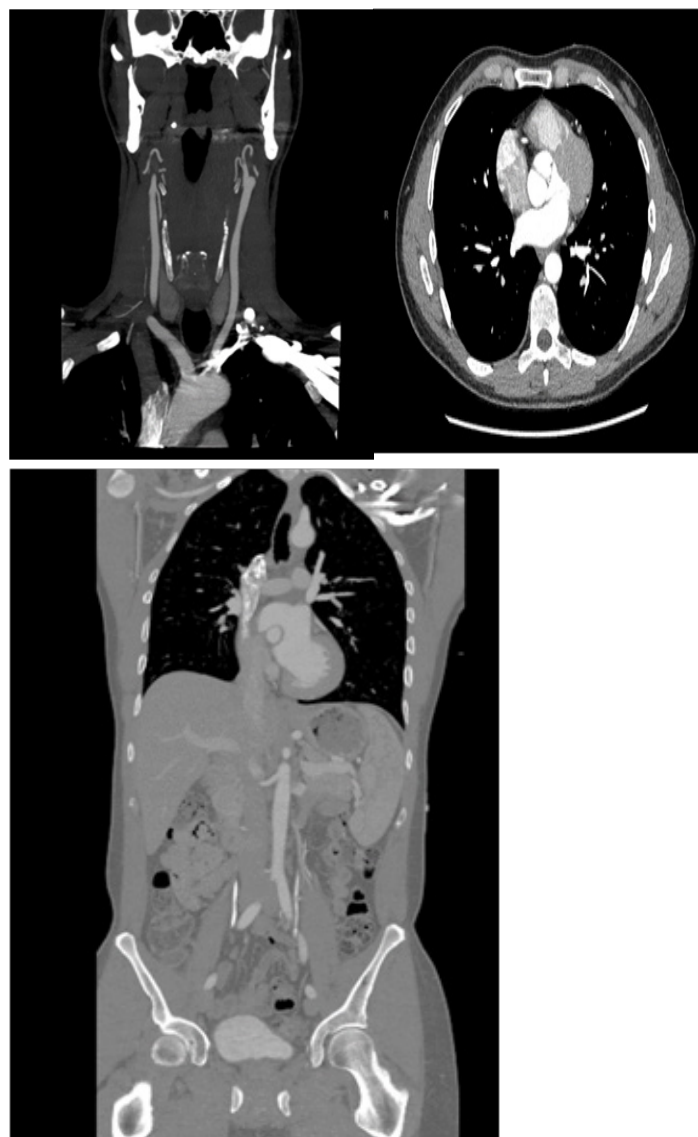


Figure 3: Computed Tomography Angiographic Findings. A negative workup for fibromuscular dysplasia on CTA of the neck (a), chest (b), and abdomen (c). Chest imaging confirms presence of ascending aortic dilatation and a bicuspid aortic valve.

5. Management

Patient was treated with clopidogrel 75mg and aspirin 81mg daily for dual antiplatelet therapy (DAPT) in addition to Metoprolol succinate 12.5mg. There was no clear indication for statin therapy given the absence of atherosclerosis and blood pressure was well controlled. Patient was discharged in stable condition with referral to cardiac rehab.

6. Outcome

Patient presented 48 hours later with chest pain and recurrent STEMI on ECG. Coronary angiogram revealed a distal occlusion (99%) of the RPL1

Annals of Clinical and Medical Case Reports

with TIMI 1 flow which was successfully intervened upon with cutting balloon angioplasty of distal SCAD lesion. There was 0% residual stenosis post intervention (Figure 4). Patient was discharged 48 hours later on aspirin, clopidogrel and metoprolol succinate; however, patient presented one week later to the hospital with recurrent chest pain and NSTEMI. Troponin I peaked at 3.68 and then decreased to 1.7 the following morning. Chest pain subsided and patient was started on isosorbide mononitrate 30mg for management of angina and was discharged on otherwise similar medical management 48hr later.

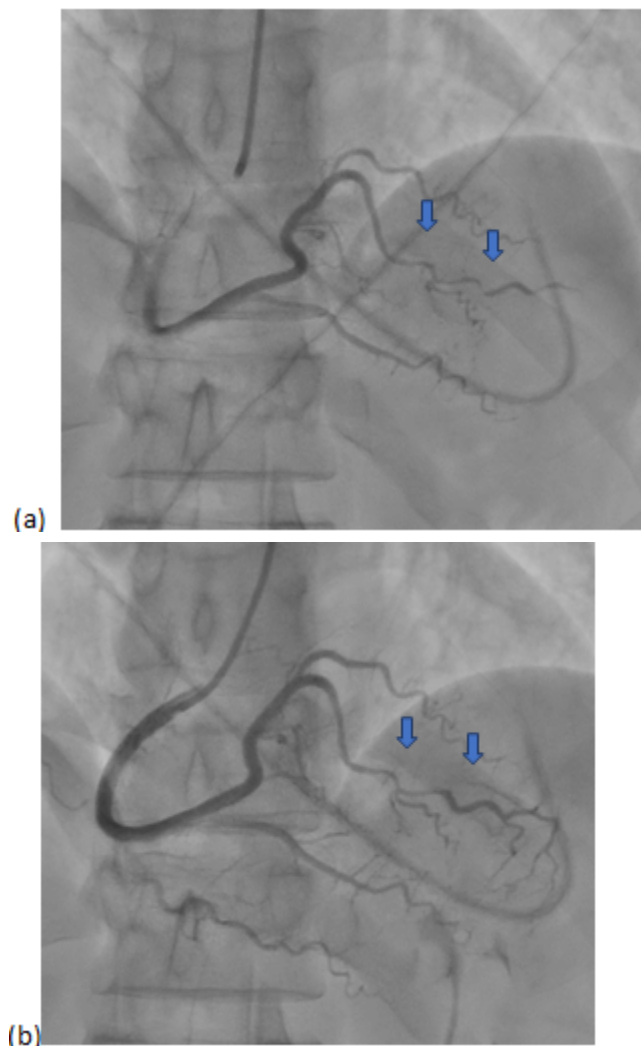


Figure 4: 2nd Coronary Angiogram with Cutting Balloon Angioplasty. Coronary angiogram showing the RPL1 SCAD lesion with a 99% subtotal occlusion (a) treated with cutting balloon angioplasty (b).

The following day, patient returned to the hospital with recurrent chest pain and NSTEMI and troponin I of 1.93. General Cardiology team and Interventional Cardiologist discussed case and agreed repeat angiogram with possible percutaneous coronary intervention (PCI) was appropriate given recurrent symptoms. Patient was transferred to the cardiac catheterization lab once more and PCI of the RPL1 dissection was

performed with placement of two Orsiro overlapping drug eluting stents (Figure 5). Limited TTE obtained during admission was unremarkable demonstrating preserved LVEF. Patient was discharged soon afterward with unchanged medical therapy in stable condition.

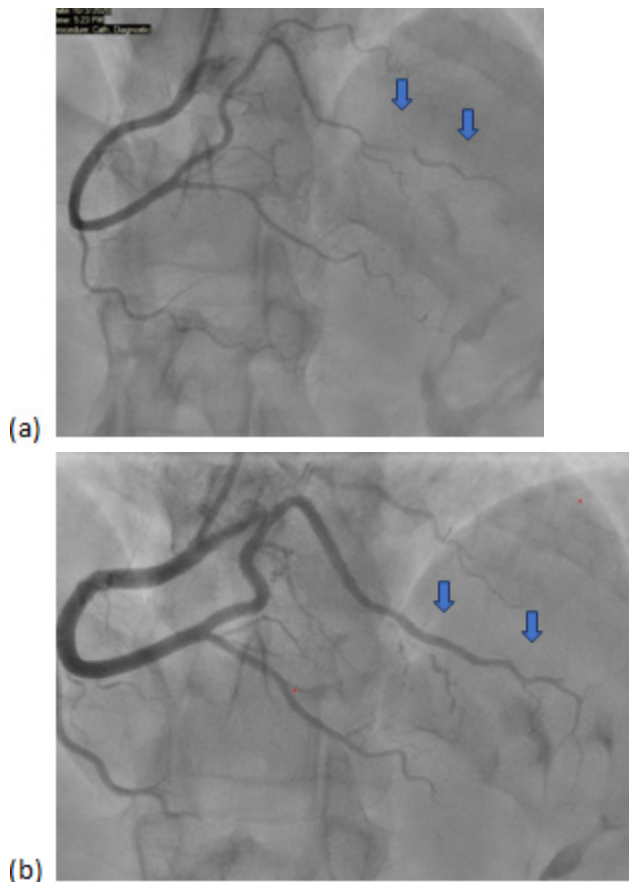


Figure 5: 3rd Coronary Angiography Findings Following PCI. Coronary angiogram showing SCAD lesion before (a) and after (b) stent placement to the right posterolateral 1 (RPL1) artery.

7. Follow Up

Patient followed up with the out-patient Cardiologist two weeks after coronary stent placement and routinely for 1 year post stent placement. He was feeling well from a cardiac perspective, tolerating current medications without noticeable side effects, and completed cardiac rehab without chest pain recurrence. He was referred for genetic testing regarding bicuspid valve and SCAD history. Physician recommended repeat transthoracic echocardiogram for annual surveillance of the dilated ascending aorta.

8. Discussion

Prevalence and Presentation

SCAD is predominantly found in females, and male cases most often present after activities involving isometric exertion [4]. Even so, our patient had no recent history of isometric exertion, but he had recently

Annals of Clinical and Medical Case Reports

completed a half marathon and the cardiovascular stress of such an activity may have been a contributing factor to his dissection. Expert reviews have advised the avoidance of high intensity endurance training in SCAD cases [5]. The currently understood factors that are associated with recurrent SCAD – FMD, extreme exertion or stress (after the first occurrence), uncontrolled hypertension, migraine headaches, and severe coronary vessel tortuosity – were not present in this case [2]. He was otherwise healthy without a significant cardiac history – not uncommon in SCAD cases. A bicuspid valve was also found on transthoracic echocardiogram, and although connective tissue disorders are highly associated with SCAD occurrence, no association between bicuspid aortic valve and SCAD has been identified at this time outside of other isolated case studies [6], [7]. Furthermore, a recent histopathological study in SCAD survivors demonstrated typical FMD arterial changes were not present in samples derived from coronary arteries – indicating SCAD vasculopathy may be independent of those changes occurring in FMD cases [8]. At the same time, other connective tissue disorders like Marfan syndrome carry a higher risk of SCAD, and histopathological findings between aortic walls in these patients resemble those with a bicuspid valve [9]. On the basis of this, an association between this aortopathy and SCAD should not be ruled out at this time.

It is unclear based on present evidence how much of a contributing factor the aortopathy associated with a bicuspid valve may be to the development of SCAD or its recurrence. While our case is consistent with retrospective data showing SCAD lesion extension within 30 days is more common than recurrent SCAD involving a new coronary artery in the same time frame [10], it will be interesting to see as literature develops if aortopathy or the presence of extra-coronary vascular abnormalities can influence or be associated with an early recurrence or lesion extension.

9. Conclusions

More data on the possible overlapping prevalence of bicuspid aortic valve in SCAD patients may shed light on how the two disease states influence one another from a prognostic standpoint (if at all). Connective tissue diseases have been demonstrated as a risk factor for SCAD. It would be interesting to elucidate whether bicuspid aortic valve aortopathy, which has similar histological findings to aortopathy in patients with Marfan syndrome, increases the risk for SCAD. In addition, future studies should investigate sex-based influence on treatment response and outcomes, but given the relative dearth of males in SCAD cohorts, this question remains difficult to answer for the time being.

10. Abbreviations and Acronyms:

ACS - Acute Coronary syndrome; ECG – Electrocardiogram; ED – Emergency Department; DAPT – Dual Antiplatelet Therapy; FMD – Fibromuscular Dysplasia; LVEF – Left Ventricular Ejection Fraction; PCI – Percutaneous Coronary Intervention; RPL1 – Right posterolateral artery; SCAD – Spontaneous Coronary Artery Dissection; STEMI – ST

Segment Myocardial Infarction; TTE – Transthoracic Echocardiogram

Reference

1. Hayes SN, Tweet MS, Adlam D, et al. Spontaneous Coronary Artery Dissection: JACC State-of-the-Art Review. *J Am Coll Cardiol.* 2020; 76(8): 961-984. DOI: 10.1016/j.jacc. 2020.05.084
2. Saw J, Humphries K, Aymong E, et al. Spontaneous Coronary Artery Dissection: Clinical Outcomes and Risk of Recurrence. *J Am Coll Cardiol.* 2017;70(9):1148-1158. doi:10.1016/j.jacc. 2017.06.0533. Abdulkareem N, Smelt J, Jahangiri M. Bicuspid aortic valve aortopathy: genetics, pathophysiology and medical therapy. *Interact Cardiovasc Thorac Surg.* 2013; 17(3): 554-559.
4. Fahmy P, Prakash R, Starovoytov A. Pre-Disposing and Precipitating Factors in Men With Spontaneous Coronary Artery Dissection. *JACC Cardiovasc Interv.* 2016;9(8):866-868. <https://doi.org/10.1016/j.jcin.2016.02.024>
5. Kim, ESH. Spontaneous Coronary-Artery Dissection. *N Engl J Med.* 2020; 384(11):1077-1078. DOI: 10.1056/NEJMra2001524
6. Labombarda F, Legallois D, Sabatier R. Spontaneous coronary artery dissection and bicuspid aortic valve. *Arch Cardiovasc Dis.* 2009; 102(12): 857-858. <https://doi.org/10.1016/j.acvd.2009.08.006>.
7. M Schettino, M Rezzaghi, G Caretta, G Tonelli, M Arena, A Menozzi, I Porto, P134 RECURRENT SCAD IN A PATIENT WITH BICUSPID AORTIC VALVE AND ANOMALOUS CORONARY ORIGIN. *European Heart Journal Supplements.* 2023; 25 Supp D: PD92; doi.org/10.1093/eurheartjsup/suad111.216
8. Margaritis M, Saini F, Baranowska-Clarke AA, et al. Vascular histopathology and connective tissue ultrastructure in spontaneous coronary artery dissection: pathophysiological and clinical implications [published online ahead of print, 2021 May 28]. *Cardiovasc Res.* 2021; cvab183. doi:10.1093/cvr/cvab183
9. Nataatmadja M, West M, West J, et al. Abnormal extracellular matrix protein transport associated with increased apoptosis of vascular smooth muscle cells in marfan syndrome and bicuspid aortic valve thoracic aortic aneurysm. *Circulation.* 2003; 108 Suppl 1:II329-II334. doi:10.1161/01.cir.0000087660.82721.15
10. Main A, Prakash R, Starovoytov A, et al. Characteristics of extension and de novo recurrent spontaneous coronary artery dissection. *EuroIntervention.* 2017; 13(12):e1454-e1459. Published 2017 Dec 8. doi:10.4244/EIJ-D-17-00264